The American Journal of Sports Medicine
http://ajs.sagepub.com/

# Trochleoplasty as a Solitary Treatment for Recurrent Patellar Dislocation Results in Good Clinical Outcome in Adolescents

Carlo Camathias, Katrin Studer, Ata Kiapour, Erich Rutz and Patrick Vavken

*Am J Sports Med* published online July 19, 2016
DOI: 10.1177/0363546516652894

The online version of this article can be found at:
http://ajs.sagepub.com/content/early/2016/07/19/0363546516652894

Published by:
SAGE
http://www.sagepublications.com

On behalf of:
American Orthopaedic Society for Sports Medicine
AOSSM

AJSM PreView, published on July 19, 2016 as doi:10.1177/0363546516652894

# Trochleoplasty as a Solitary Treatment for Recurrent Patellar Dislocation Results in Good Clinical Outcome in Adolescents

Carlo Camathias,*†‡ MD, Katrin Studer,† MD, Ata Kiapour,‡ PhD, Erich Rutz,† MD, and Patrick Vavken,†‡§ MD
*Investigation performed at the University Children's Hospital Basel (UKBB), Basel, Switzerland*

**Background:** The essential static patellar stabilizer is a normal-shaped trochlear groove. A dysplastic groove destabilizes the patella. Trochleoplasty approaches this underlying condition and reshapes the trochlea. However, studies have reported on trochleoplasty for revision cases or as accompanied by other interventions. The effect of trochleoplasty alone remains unexplained.

**Purpose:** To introduce trochleoplasty as a stand-alone treatment for recurrent patellar dislocation and to compare its pre- to postoperative functional and clinical variables.

**Study Design:** Case series; Level of evidence, 4.

**Methods:** A trochleoplasty was performed in 50 knees (27 right) in 44 patients (30 females; mean ± SD age, 15.6 ± 2.0 years). The indication for surgery was recurrent patellar dislocation not responding to nonoperative treatment (>6 months), with types B through D dysplasia and closed or closing physes in adolescents aged 10 to 20 years. Assessment included J-sign and apprehension test, Kujala and Lysholm scores, patients' subjective assessment and activity level according to the International Knee Documentation Committee questionnaire, and patients' overall satisfaction. The Caton-Deschamps ratio and the lateral condyle index were measured. Pre- versus postoperative values were compared with a paired Wilcoxon signed-rank test. The minimum follow-up was 24 months (33 ± 10.6 months).

**Results:** The Kujala score improved from 71 preoperatively to 92 postoperatively ($P < .001$) and the Lysholm score from 71 to 95 ($P < .001$). Patients' subjective assessment improved at the final follow-up as compared with that preoperatively ($P < .001$). Most patients enhanced their activity ($P < .001$), and their overall satisfaction increased postoperatively ($P < .001$). Preoperatively, there was a positive J-sign in 45 knees and a positive apprehension test in 41 knees. Both markers disappeared postoperatively in 39 and 33 knees, respectively, leaving 6 knees with a positive J-sign and 8 knees with a positive apprehension test ($P < .001$). One patella redislocated postoperatively after 38 months. Four patients required a single arthroscopic debridement.

**Conclusion:** In this study, trochleoplasty as a solitary treatment for recurrent patellofemoral dislocations in patients with trochlear dysplasia resulted in good clinical outcomes if severe torsional and axial malalignment was excluded. Kujala and Lysholm scores increased postoperatively, as well as subjective International Knee Documentation Committee assessment of outcomes, activity level, and overall satisfaction.

**Keywords:** patellar dislocation; trochleoplasty; trochleoplasty; clinical outcomes; adolescent

Patellofemoral instability is a common issue in adolescents. As a rule of thumb, 1 in 6 cases will recur, and 2 in 6 patients will have continuous symptoms. There are 3 major contributors to patellar stability: passive, static, and active stabilizers. According to Desio et al,[12] passive stabilization is afforded by the medial patellofemoral ligament (MPFL). Senavongse and Amis[37] showed in their research that the force to displace the patella is less during the first 20° of flexion. The force decreases from approximately 140 N to <80 N if the MPFL is insufficient. In contrast, the most important static stabilizer is the trochlea. In addition, according to Senavongse and Amis, a flat or dysplastic trochlea reduces the force required to displace the patella during the entire range of motion. The MPFL

*Address correspondence to Carlo Camathias, MD, Paediatric Orthopedic Department, University Children's Hospital Basel (UKBB), Spitalstrasse 33, CH-4056 Basel, Switzerland (emails: carlo.camathias@ukbb.ch; camathias.carlo@gmail.com).

†Paediatric Orthopedic Department, University Children's Hospital Basel (UKBB), Basel, Switzerland.

‡Department of Orthopedic Surgery, Boston Children's Hospital, Harvard Medical School, Boston, Massachusetts, USA.

§Alpha Clinic Zurich, Zurich, Switzerland.

One or more of the authors has declared the following potential conflict of interest or source of funding: Funding for this study was received from the Merian Iselin Foundation Basel.

The American Journal of Sports Medicine, Vol. XX, No. X
DOI: 10.1177/0363546516652894

and trochlea are stabilizers near full extension. Both structures decrease the restraining force from 140 N to 80 N within the first 20° of flexion in the case of an insufficient MPFL or a dysplastic trochlea. Therefore, the trochlea is just as important as the ligament near full extension. However, since a patella alta is common in patients with patellofemoral instability, it is probably true that the patellar groove tracks the patella later, and the MPFL is regarded as more important near full extension of the knee.[1,37]

In >80% of all patients with patellar dislocation, such dysplastic trochleae are present and are considered to be the primary condition for recurrence.[10,11,44] The trochleoplasty approaches this underlying condition and reshapes the trochlea. Previous studies state good functional results and stable patellas.[‖] However, all studies report on trochleoplasty for revision cases or as accompanied by other interventions (ie, femoral or tibial osteotomy and soft tissue interventions). The single effect of the trochleoplasty remains unexplained and is questioned to be sufficient for stabilizing a recurrent dislocating patella.[6,15,29,30]

The purposes of this study are therefore to introduce a modified trochleoplasty with lengthening of the lateral condyle, inspired by the well-known technique of Bereiter and Gautier,[4] as a stand-alone treatment for recurrent patellar dislocation and to compare its pre- and postoperative functional and clinical variables. We present 50 cases with a minimum follow-up of 2 years.

## METHODS

We conducted this work at a tertiary care pediatric orthopaedic hospital as a cohort study, approved by the responsible institutional review board (University of Basel No. 2013/104).

Between 2010 and mid-2013, a single consultant (C.C.) treated 148 knees with patellar dislocations: 114 knees with recurrent patellar dislocations and 34 with a first patellar dislocation. The 34 subjects with a first dislocation were treated nonoperatively, with physical therapy and a splint. Within the time frame of 3 years, 8 of these patients with a first event developed recurrent dislocations (>3 times). Therefore, a total of 122 knees with a recurrent patellar dislocation were treated. All patients were primarily handled nonoperatively, with a physical therapy regimen and knee braces for at least 6 months. If the nonoperative treatment failed, the patient was considered a candidate for an operative procedure. Of these 122 knees, 27 did not fulfill criteria for further patellofemoral treatment: 2 patients had a completely deformed arthritic knee without any patellofemoral cartilage, which made an arthroplasty necessary; 15 patients reported no complaints at all after the nonoperative treatment; and 10 patients still reported patellar dislocations or other complaints but were unwilling to consider any surgical procedures. In 18 knees in patients <12 years old, we stabilized the patella with an MPFL reconstruction (quadriceps tendon). In the remaining 77 knees (69 patients), a single surgeon (C.C.) performed a trochleoplasty.

The indications for trochleoplasty and criteria for study inclusion were an adolescent patient aged 10 to 20 years, recurrent patellar dislocations not responding to at least 6 months of nonoperative treatment, and minimum type B dysplasia according to Dejour et al[9,10] and closed or closing physes (grade V or VI according to Dvorak et al,[17] with grade V indicating <5 mm on any single section on magnetic resonance imaging [MRI] and grade VI indicating completely fused physis).

Patients were excluded from this study in the case of previous lower limb operations (n = 7) or systemic diseases (cerebral palsy; n = 2). We also excluded patients with open physis (less than grade V[17]), in which we performed a trochleoplasty (n = 15), and those with additional surgical interventions (osteotomies for torsional or valgus/varus correction; n = 3). Of these 27 knees, 6 had >1 exclusion criterion (additional and previous surgery, cerebral palsy, or open physis). Other exclusion criteria were ligamentous trauma (except MPFL), abnormal femoral torsion >25° (assessed with radiographs according to Dunn[16]), abnormal tibial torsion >25° (assessed clinically), valgus or varus of the knee (deviation of mechanical axis >1 cm from midline as evaluated on a standing whole-leg radiograph), infection in the knee, or lack of informed consent. Dysplastic trochleae type A (shallow trochlea) was considered a contraindication for trochleoplasty. However, at this stage, no knee showed a type A dysplasia.

In the remaining 50 knees (27 right) in 44 patients (30 females; mean ± SD age, 15.6 ± 2.0 years; range, 13-20.4 years), trochleoplasty was performed as a stand-alone treatment for patients with recurrent patellar dislocations (Figure 1).

Preoperative MRI was used to classify the type of trochlear dysplasia (A to D, corresponding to Dejour classification[9,10]): 27 knees were recognized as type B, 17 knees as type C, and 6 knees as type D. Type A dysplasia was not found in this cohort (Figure 2).

### Surgical Technique

A Supplementary Video of the surgical technique is available online. The patient was positioned supine without a tourniquet. A skin incision 6 to 10 cm long was made lateral and superior to the patella. The iliotibial band without the underlying joint capsule was split distally toward the Gerdy tubercle and proximally as far as possible. The joint capsule was incised lateral to the patella and along the lateral edge of the patellar tendon to the border of the lateral meniscus. With this arthrotomy, the trochlea could be exposed (Figure 3A).

Next, we mobilized the vastus lateralis from the femur with a finger to release tension on the muscle. A Hohman retractor, inserted medially in the area of the medial epicondyle, displaced the patella medially (Figure 3A). Two K-wires (2.0 mm), positioned medially to the trochlear groove, retracted the patella and also the quadriceps tendon. To visualize the mechanical axis of the lower limb, we drew a virtual line from the notch to the anterior

[‖]References 9, 14, 18, 19, 24, 28, 29, 31, 34, 36, 42, 43, 44, 46.

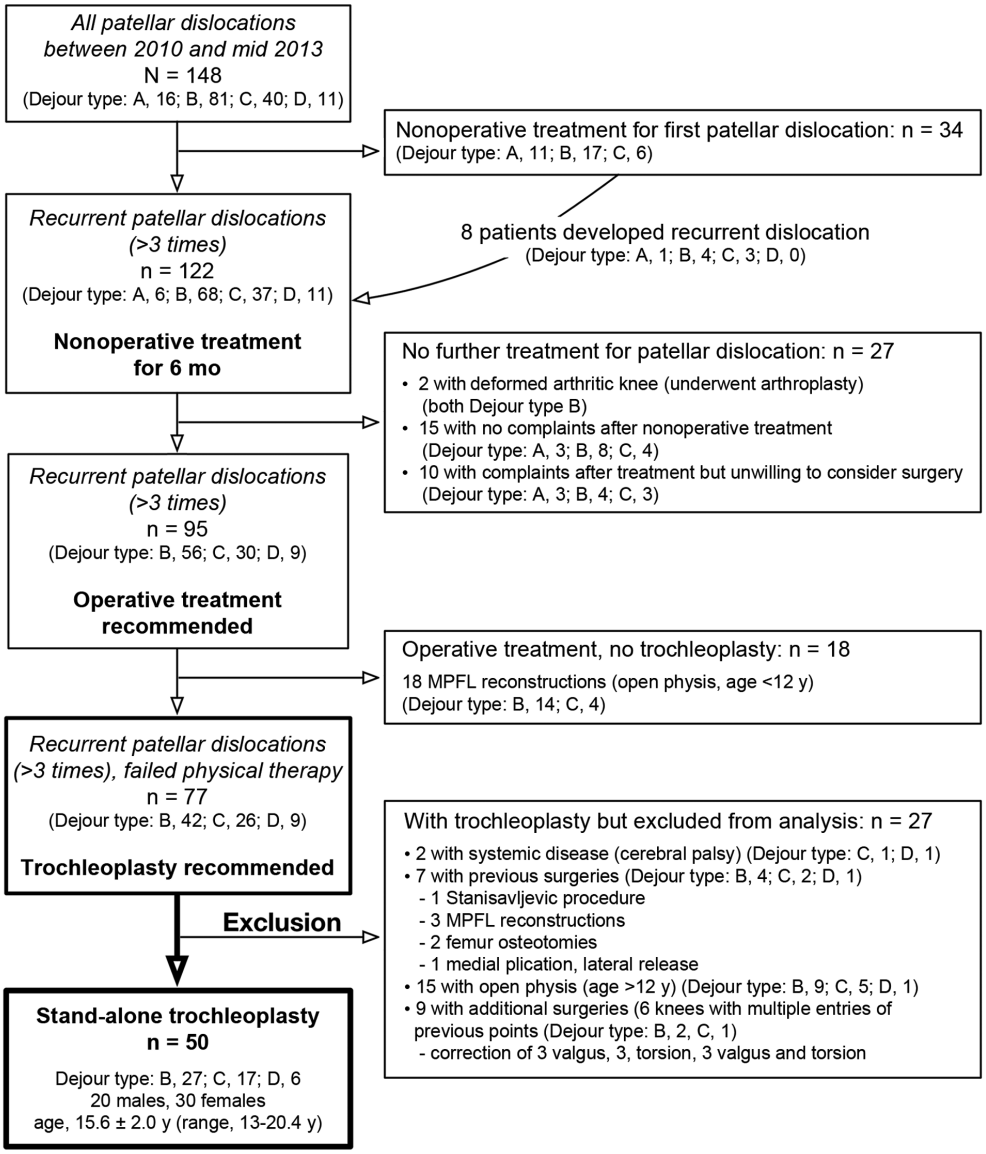


**Figure 1.** Flowchart of selection of patients/knees. No patient was lost to final follow-up. N, n = number of treated knees. Dejour refers to the classification of trochlea according to Dejour and Saggin.[9] MPFL, medial patellofemoral ligament.

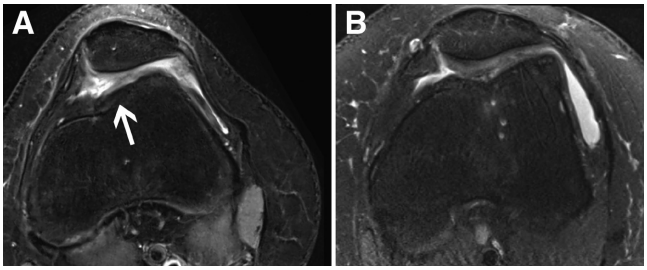


**Figure 2.** T2-weighted magnetic resonance imaging scan left knee, axial view below the proximal entrance of the trochlea. (A) Preoperative scan with dysplasia type B with a bump (arrow). (B) Postoperative after trochleoplasty. Trochlea without a bump and centralized patella.

superior iliac spine. This line also determined the direction of the new trochlear groove and its proximal entrance. We marked this entry with a third K-wire placed 2 cm proximally to the cartilage (Figure 3B).

A sharp elevator was used to detach the periosteum surrounding the trochlea, leaving approximately 1 cm of the periosteum still connected to the cartilage. On the lateral part of the trochlea, a triangular periosteal flap of about 2 cm was left attached to the cartilage (Figure 3B). Then, with an 8-mm curved chisel, we elevated the cartilage on the lateral edge of the lateral condyle (Figure 3B). Subsequently, to peel off an osteochondral layer, we used a 13-mm chisel extending into the intercondylar notch (Figure 3C). A flat, straight, 35- to 40-mm osteotome was used to remove a triangular bone block of about 2 to 3 cm from the center of the

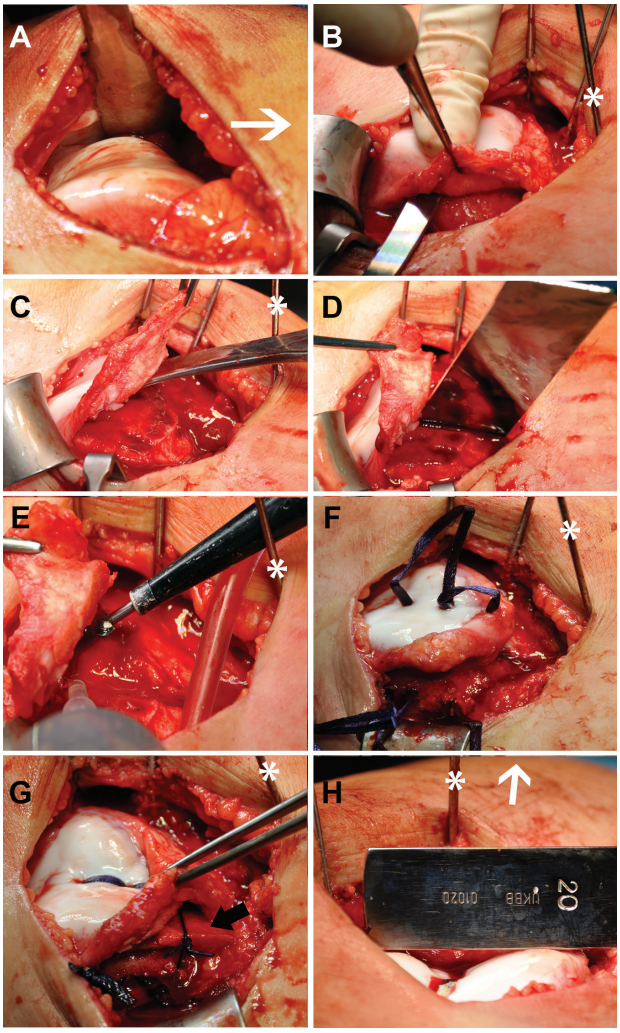


**Figure 3.** Left knee, view from lateral. (A) A bump is visible at the entrance of the trochlea, indicating a dysplasia type B (white arrow pointing to the hip). (B) The periosteum is detached around the cartilage. With a small chisel, the lateral edges of the trochlea are elevated. (C) Osteochondral flake is peeled off. (D) A triangular bone block is removed with a straight bit. (E) The subchondral groove is smoothed with a high-speed bur. (F) Fixation of osteochondral flake with 2 Vicryl bands lined up with the new trochlear groove. (G) Bone block (black arrow) is fixed between the proximal part of the lateral osteochondral flake and the femur. (H) New trochlea (view from distal to proximal with a white arrow pointing to the hip). A 20-mm chisel marks the line between the condyles. Asterisk (*) indicates the third K-wire, which determines the direction of the new trochlear groove. Of note, with the anatomy restored, the patella rides up on the condylar ridges when the knee extends. This reduces contact between the kneecap cartilage and the Vicryl tape.

dysplastic trochlea along the planed virtual line directed toward the third K-wire. This roughly formed the new trochlea groove. The removed bone block was required later for lengthening the lateral condyle (Figure 3D). A high-speed bur was used to smooth out this subchondral groove, with the entrance always directed to the third K-wire. The osteochondral layer was thinned out if needed and then gently molded into the new groove with a blunt elevator (Figure 3E). At this point, a concave trochlear groove had already been established. We fixed the cartilage transosseously on the lateral side of the femur with two 3-mm Vicryl bands (Ethicon, Johnson & Johnson). For this purpose, two 3-mm holes were drilled through the cartilage and 1 right at the entrance of the trochlear groove. All holes lined up with the new trochlear groove (Figure 3F). With a new groove established so that the patella could glide on the ridges of the condyles close to extension, contact of the patella and the Vicryl tape was reduced.

With the cartilage fixed again to the central groove in the femur, the harvested bone block was used to lengthen the lateral condyle to afford lateral stabilization near full extension. Therefore, the bone block was placed under the osteochondral layer at the proximal extension of the lateral femoral condyle. The bone block and the cartilage overlapped 1 cm approximately. This step elevated the lateral condyle minimally, however, lengthening the lateral part of the condyle (and trochlea) 1 to 2 cm. The bone block was secured additionally with a transosseous Vicryl 2 suture (Ethicon, Johnson & Johnson) (Figure 3, G and H). To cover the bone, the periosteum left as an extension of the osteochondral layer was closed (Vicryl 2-0). The knee capsule and the lateral retinaculum were sutured separately with a Vicryl 2-0 and a Vicryl 2, respectively.

Postoperatively, a knee brace allowing up to 60° of flexion was applied for 6 weeks. Physical therapy with active and passive range of motion exercised the knee immediately after the operation. Partial weightbearing with one-half body weight was allowed on the operative side and gradually increased after 6 weeks. We permitted return to all kinds of sports after 6 months. The follow-up time was 33 ± 10.6 months (range, 24-64 months), with a minimum of 24 months per patient. No patient was lost to final follow-up.

## Study Endpoints and Follow-up

All patients were followed in a specialist pediatric knee clinic. Besides the usual orthopaedic examination, we assessed the J-sign and the apprehension test clinically, as well as Kujala and Lysholm scores.[25,40] Every patient was asked pre- and posttreatment for a subjective assessment, an estimate of his or her activity level, and an overall satisfaction rating according to the International Knee Documentation Committee (IKDC) questionnaire[20] (grading for subjective assessment and overall satisfaction: A = excellent, B = good, C = adequate, and D = poor ). To assess patellar height, we calculated the Caton-Deschamps ratio (>1.3 corresponds to a patella alta), and to evaluate the length of the lateral condyle, we calculated the lateral condyle index (LCI; <0.90 corresponds to a short lateral condyle)[5,8] (Figure 4). Additionally, a sulcus angle was measured on the axial plane 3 cm above the tibiofemoral articulation.[32] All values were collected before the index operation and were compared with postoperative data at the final follow-up.

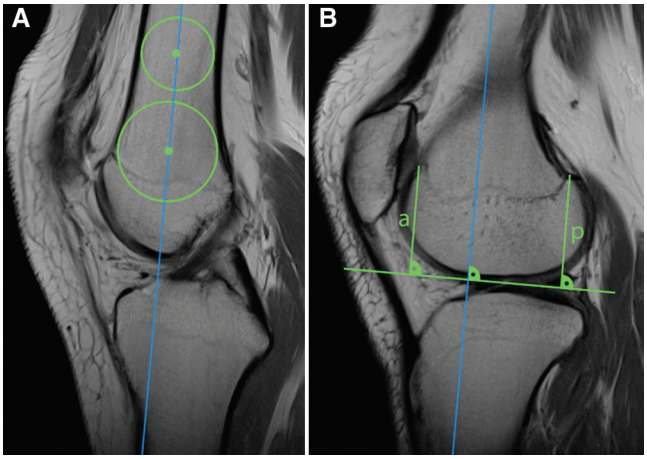


**Figure 4.** Magnetic resonance imaging measurement of the lateral condyle index according to Biedert et al[5]: (A) Two circles indicate the central axis on a sagittal image showing the anterior cruciate ligament in its entire length. (B) The most lateral image on which the cartilage still can be seen. A tangent is drawn orthogonal to the central axis. The length (*a* and *p*) to the most anterior and posterior aspects of the cartilaginous part is measured in relation to the tangent line. Its ratio (*a*:*p*) represents the lateral condyle index.

One year after the trochleoplasty, we repeated the MRI and measured the sulcus angle and the tibial tuberosity–trochlear groove (TTTG) distance.[35] We did not measure the TTTG distance preoperatively, for 2 reasons: First, the reference point to measure the TTTG distance in a dysplastic trochlea is not defined. Measuring the trochlea more distal or proximal can change the TTTG distance significantly.[41] Positioning the patient differently during MRI also influences the TTTG distance.[7,13,23] Since we did not standardize our MRI protocol and did not control the patient's knee flexion and rotation, our TTTG distance measurements are potentially unreliable on preoperative scans.

## Statistical Analysis

Analysis was performed with a standard statistical software package (JMP v 10; SAS Institute). Data were not normally distributed (tested with Shapiro-Wilk, $P < .001$). Therefore, all continuous values were compared with a matched paired Wilcoxon signed-rank test. Ordinal and nominal data were compared using the matched paired Wilcoxon signed-rank test and the chi-square test, respectively. Also, we analyzed the endpoints among Dejour subgroups with nonparametric analysis of variance with a post hoc Steel-Dwass to correct for multiple comparisons. Additionally, a post hoc power analysis to detect a difference of 10 points in the Kujala or Lysholm score among the postoperative groups was performed. With an alpha of 0.05 and a beta of 0.8, we calculated an effect size of 0.92, resulting in a total sample size of 15.

## RESULTS

The Kujala score improved from 71 preoperatively to 92 postoperatively ($P < .001$) (Table 1). The pre- and postoperative scores did not differ among subgroups with a different grade of dysplasia (B to D; $P = .82$). The Lysholm score rose from 71 preoperatively to 95 postoperatively ($P < .001$) (Table 1). Also here, pre- and postoperative scores did not differ among subgroups (B to D; $P = .67$). Patient subjective assessment (IKDC score) increased at the final follow-up, with more patients in grade A as compared with preoperative assessment ($P < .001$) (Table 1). Preoperatively, most patients participated at a low level but enhanced their activity (IKDC) postoperatively ($P < .001$), and their overall postoperative satisfaction increased significantly ($P < .001$) (Table 1).

Preoperatively, we detected a positive J-sign in 45 knees and a positive apprehension test in 41 knees. Both clinical markers disappeared postoperatively in 39 and 33 knees, respectively, leaving 6 knees with a positive J-sign and 8 knees with a positive apprehension test ($P < .001$ for both values, $\chi^2$ test).

We calculated a mean Caton-Deschamps index of 1.45 ± 0.29 (95% CI, 1.36-1.53), indicating a high-riding patella (>1.3) in 72% (n = 36) of all patients. The mean LCI was 0.86 ± 0.11 (95% CI, 0.83-0.88), indicating too short a lateral condyle (<0.90) in 56% (n = 28). Patients with a positive J-sign postoperatively had a higher Caton-Deschamps index (mean difference ± SE, 0.33 ± 0.07; $P < .001$), but they did not have significantly different Kujala and Lysholm scores as compared with patients with a negative J-sign ($P = .39$). However, the post hoc power was very low (0.14) for the latter statement (Kujala and Lysholm scores). Patients with a positive apprehension test postoperatively had a lower Kujala score (mean difference ± SE, 8.9 ± 3.3; $P < .01$) as compared with patients with a negative apprehension test. The Caton-Deschamps index and Lysholm score did not differ ($P = .41$), again with a small post hoc power (0.29) (Table 2). All patients with a positive J-sign postoperatively and most patients with a positive apprehension sign postoperatively had a patella alta (Table 3).

We measured the sulcus angle with a preoperative mean ± SD of 184.1° ± 8.5°, which decreased postoperatively to 136.1° ± 6.2° ($P < .0001$). The TTTG distance postoperatively was 11.2 ± 2.5 mm.

Out of 50 knees, 1 patella redislocated postoperatively after 38 months. In this female patient, an underlying Noonan syndrome, which goes along with a generalized laxity, complicated the treatment. The knee was revised with a retrochleoplasty combined with an MPFL-plasty. The further course was uneventful. An additional 4 patients underwent revision surgery. In these cases, intra-articular scar tissue impeded, disturbed, and reduced the range of motion (–30° flexion). These patients required a single arthroscopic debridement of the knee to release the adhesions. No other complications were recorded in this series.

Additional information concerning the relationship among the J-sign, apprehension sign, the Dejour classification, and the radiologic and clinical scores is summarized in the Appendix (available online at http://ajsm.sagepub.com/supplemental).

TABLE 1
Comparison of Pre- and Postoperative Values (N = 50 Knees)[a]

| | Kujala Score | | Lysholm Score | | IKDC Questionnaire[20] Result[b] | | |
|---|---|---|---|---|---|---|---|
| | Mean ± SE | 95% CI | Mean ± SE | 95% CI | Subjective Patient Assessment | Activity Level | Patient Satisfaction |
| Preoperative | 71 ± 1.1 | 69.0-74.5 | 71 ± 1.6 | 68.1-74.5 | A:0, B:18, C:28, D:4 | I:6, II:6, III:25, IV:13 | A:5, B:21, C:19, D:4 |
| Postoperative | 92 ± 0.8 | 90.2-93.6 | 95 ± 0.7 | 94.1-96.8 | A:25, B:18, C:3, D:0 | I:27, II:17, III:4, IV:2 | A:32, B:16, C:1, D:0 |
| Difference | 20.8 ± 1.2 | 18.3-23.3 | 23.7 ± 1.6 | 20.5-26.9 | | | |
| *P* value[c] | **<.0001** | | **<.0001** | | **<.0001** | **<.0001** | **<.0001** |

[a]Bolded *P* value indicates statistically significant difference between pre- and postoperative results. IKDC, International Knee Documentation Committee.
[b]Grading for subjective assessment and satisfaction: A, normal; B, nearly normal; C, abnormal; D, severely abnormal. Grading for activity level: I, jumping, pivoting, hard cutting, football, soccer; II, heavy manual work, skiing, tennis; III, light manual work, jogging, running; IV, sedentary work (activities of daily living).
[c]Paired Wilcoxon signed-rank test.

TABLE 2
Comparison of Postoperative Values Between Groups With a Positive J-Sign and Apprehension Sign[a]

| | Caton-Deschamps Ratio | | Kujala Score | | Lysholm Score | |
|---|---|---|---|---|---|---|
| | Mean ± SE | 95% CI | Mean ± SE | 95% CI | Mean ± SE | 95% CI |
| J-sign | | | | | | |
| Negative (n = 44) | 1.41 ± 0.28 | 1.32-1.50 | 91 ± 0.9 | 89.7-93.6 | 95 ± 0.7 | 93.7-96.7 |
| Positive (n = 6) | 1.74 ± 0.06 | 1.59-1.89 | 94 ± 0.9 | 91.5-96.5 | 97 ± 1.4 | 93.4-100 |
| Difference | 0.33 ± 0.07 | 0.17-0.49 | 2.3 ± 1.3 | 0.50-5.20 | 1.80 ± 1.6 | 1.89-5.47 |
| *P* value[b] | **<.01** | | .39 | | .47 | |
| Apprehension sign | | | | | | |
| Negative (n = 42) | 1.43 ± 0.04 | 1.34-1.51 | 93 ± 0.60 | 92.2-94.5 | 95 ± 0.6 | 94.5-97.2 |
| Positive (n = 8) | 1.56 ± 0.13 | 1.25-1.85 | 84 ± 3.2 | 76.7-92.3 | 93 ± 2.5 | 87.4-99.0 |
| Difference | 0.13 ± 0.13 | 0.18-0.43 | 8.9 ± 3.3 | 1.10-16.7 | 2.6 ± 2.5 | 8.5-3.2 |
| *P* value[b] | .18 | | **<.01** | | .41 | |

[a]Bolded *P* value indicates statistically significant difference between negative and positive results.
[b]Wilcoxon signed-rank test.

TABLE 3
Comparison of Groups With Postoperative Patella Alta and Normal Patellar Height[a]

| | | J-Sign | | Apprehension Sign | | | |
|---|---|---|---|---|---|---|---|
| | Caton-Deschamps Ratio | Negative | Positive | Negative | Positive | Kujala Score | Lysholm Score |
| Patella alta[b] (n = 36) | 1.54 ± 0.19 | 30 (60) | 6 (12) | 30 (60) | 6 (12) | 92 ± 6.5 | 95.2 ± 4.8 |
| Normal patella[c] (n = 14) | 1.11 ± 0.15 | 14 (28) | 0 (0) | 12 (24) | 2 (4) | 91.8 ± 4.1 | 96 ± 4.5 |
| Total (N = 50) | | 44 (88) | 6 (12) | 42 (84) | 8 (16) | | |

[a]Values are presented as mean ± SD or n (%), with percentage based on N = 50 knees.
[b]Caton-Deschamps >1.3.
[c]Caton-Deschamps <1.3

## DISCUSSION

This study demonstrates that our modified trochleoplasty, as a solitary treatment for recurrent patellofemoral dislocations in patients with trochlear dysplasia, results in good clinical outcomes. Kujala and Lysholm scores, the subjective IKDC questionnaires, and the overall satisfaction had increased at the follow-up as compared with preoperative values. Moreover, the postoperative activity level improved in most patients. One patella redislocated postoperatively after 38 months with the need for revision. Additionally, 4 cases required an arthroscopic debridement to release scar tissue.

Trochleoplasty is an accepted concept for treating patellar instability, with several authors promoting and highlighting their techniques and outcomes. Nevertheless, each technique has its advantages and disadvantages. The Albee technique elevates the lateral condyle with

a bony wedge, which possibly increases the pressure on the lateral condyle and could lead to early-onset osteoarthritis.[36] In contrast, the Dejour or Bereiter technique deepens the trochlea without elevation or with minimal elevation of the lateral condyle.[9,44] These techniques and various others consistently have good clinical results with few patellar redislocations.[¶] Our findings are consistent with them. Our data suggest a similar outcome for all types of dysplasia (B to D), even in a type C dysplastic trochlea, which is considered a hypoplastic medial facet. However, in contrast with all previous studies, ours compared only patients with the trochleoplasty as the primary and stand-alone procedure without earlier or additional interventions. Also, as the principal difference to the Bereiter technique, ours lengthened the lateral condyle proximally with a bone block. This additional step was added for 2 reasons: first, a patella alta is considered a risk factor for instability.[11] We noted a patella alta (Caton-Deschamps >1.3) in 72% of all our cases. Compared with previous studies, this result seems to be overrated: the Dejour cohort of 143 patients noted only 24%, and other authors described up to 58% of all cases presenting with a patella alta.[11,14,26,36,45] However, we believe that a selection bias might have contributed to this effect—namely, we selected only patients with trochlear dysplasia as the predominant abnormality. The role of that relationship is as yet unclear but seems worthy of further investigation. Second, similar to the patella alta, a too short lateral condyle (LCI < 0.90) is a relevant factor in lateral patellar instability, as emphasized by Biedert et al.[5] Fifty-six percent of our study cohort expressed this element. In only 4 patients (8%) were both factors (patellar height, LCI) normal. Therefore, both scenarios (patella alta, short lateral condyle) provide too short a trochlea in which the patella engages later during knee flexion. In consequence, lengthening the lateral condyle enables the patella to be guided earlier during flexion. The lengthening part of the operation can be adjusted to the needs of a particular patient.

Also, lengthening the lateral condyle might influence the J-sign. Although the anatomic cause of the J-sign is not yet defined, it is often detected in patellar instability or a patella alta. It is thought to be positive if the patella, in maximal extension of the knee, has no trochlear guidance anymore.[33] In our cohort, the appearance of the J-sign decreased significantly postoperatively, leaving 6 knees still positive (12%). Interestingly, the remaining 6 positive knees featured a significantly higher Caton-Deschamps index than the rest of the cohort. Even if the functional scores were not inferior as compared with the rest, the only patellar redislocation was noted in this subgroup. Therefore, we believe that a very high Caton-Deschamps index limits the lengthening part of our intervention. In these cases, a combination with an MPFL-plasty, distalizing the tuberosity or soft tissue techniques for shortening the patellar tendon, might be more favorable.[3,29,39]

The apprehension test was positive postoperatively in 8 patients (16%). The Kujala score improved less in these patients. A positive test is possibly linked to a patella alta with the same consequence as already noted; however, for such a statement, our power is too low.

Different from previous cohorts, our patients were clearly younger (mean age, 15.6 years) and had a high capacity to cope. In most cases, instability without pain was the main complaint. Unfortunately, patellofemoral scores focus mainly on pain rather than pure instability. These notions might explain the good results within the scores. Also, in contrast to other studies, ours did not include patients with previous operations. This fact could positively influence outcomes. Furthermore, in a young population with less degenerated trochlear cartilage, trochleoplasty should apparently result in better short-term outcomes as compared with those of older patients with degenerations. However, the trochleoplasty fulfilled the goal of stability in this high-demanding population, as shown in increased satisfaction rates. We excluded skeletally immature patients with wide-open physes, in which we did an MPFL-plasty (age <10 years; 18 subjects). We also excluded patients with still open but premature physes, in which we did a trochleoplasty (15 subjects). We believe that these patients should be evaluated separately with all their characteristics and complication profiles.

While the MPFL (passive) provides stability during only the first 20° of flexion, a regular trochlea (static) stabilizes the patella during the entire range of motion. The amount to dislocate the patella in extension, in case of a torn MPFL or a flat trochlea, is similar.[37] In consequence, a flat trochlea leaves most of the stabilizing work to the MPFL, which makes a torn MPFL a symptom of a dysplastic trochlea.

Despite the good stability, what remains undefined is the further course of the cartilage after such a massive operative impact. Although there is only 1 study reporting on long-term results with patellofemoral degenerations in 30% of all cases, it might be reasonably assumed that these knees will all end in arthritis in the long run.[44] However, patients with >6 patellar dislocations will probably suffer arthritis anyway, whether they were treated nonoperatively or operatively.[2,21,27] Therefore, we believe that the preexisting condition of cartilage before a treatment will seriously affect the further course. In this context, we noticed, without being able to quantify this issue, that patients with several dislocations (>6 times) presented less smooth, less elastic cartilage during trochleoplasty. This characteristic led to more cartilage fractures during the procedure, especially while pressing the cartilage layer back to the deepened groove. In this regard, trochleoplasty attempts to improve biomechanics and reduce patellofemoral reaction forces but at the cost of extended surgery times and at the expense of the cartilage.[28] However, the previous statements can be interpreted only as evidence level 5. Whether this measure can avoid arthritis is far from certain. Every dislocation and the inadequate position of the patella in the trochlear groove harm the cartilage and deteriorate the starting position for any treatment. Given these facts, we therefore believe that the trochleoplasty serves best in young patients with only a few dislocations.

In this series, 5 cases out of 50 developed a complication that made an additional operation necessary. In 1 patient,

[¶]References 9, 14, 18, 19, 24, 29, 31, 34, 36, 42, 43, 44, 46.

the patella redislocated after the index procedure. We operated on this patient with a patella alta (Caton-Deschamps ratio: 1.47) and a present Noonan syndrome, a condition that goes along with a severe, generalized laxity of all joints. In retrospect, the trochleoplasty on this type D dysplastic femur was not carried out sufficiently, with a still flat trochlea postoperatively. On revision, we deepened and lengthened the trochlea again. Because of the laxity, soft tissue procedures alone were not considered to be sufficient. Nonetheless, we additionally performed an MPFL-plasty to achieve the highest possible stability. The further course was uneventful. In another 4 cases, the arthrotomy scar formed a disturbing and painful intra-articular mass, impeding the range of motion. After an arthroscopic debridement, these problems vanished.

The weakness of this study is related to its retrospective nature (but prospectively collected variables) with no control group. Also, evaluating femoropatellar problems in adolescents is challenging owing to reduced reliability and reproducibility in current radiologic and clinical assessments.[38] Although the Kujala score is validated to assess patellofemoral problems, we share the opinion of Utting et al[42] that it focuses on measuring pain rather than instability. The same remarks can be made for the Lysholm score. Measures such as the Banff Patella Instability Instrument could be more informative concerning the quality of life and symptom-related problems.[22] However, our pre- and postoperative scores differed significantly. Therefore, we consider these scores as being not optimal but sufficient to assess patellofemoral instabilities in young adults. Since we did not control the position of the leg during MRI, all radiologic measurements (TTTG distance and sulcus angle) should be assessed with caution. Flexion or extension, as well as rotation, can change values (ie, TTTG distance). Moreover, reference points are not well defined in dysplastic knee joints.[7] Our results represent a short-term view on the procedure. Further studies are needed to assess the long-term risk of patellar redislocation.

## CONCLUSION

Trochleoplasty as a solitary treatment for recurrent patellofemoral dislocations in patients with trochlear dysplasia results in good clinical outcomes if severe torsional and axial malalignment is excluded. Kujala and Lysholm scores, as well as subjective IKDC patient assessment, overall satisfaction, and activity level, increased as compared with preoperative values.

A Video Supplement for this article is available in the online version or at http://ajsm.sagepub.com/supplemental.

## REFERENCES


1. Amis AA, Oguz C, Bull AMJ, Senavongse W, Dejour D. The effect of trochleoplasty on patellar stability and kinematics: a biomechanical study in vitro. *J Bone Joint Surg Br*. 2008;90(7):864-869.
2. Arnbjörnsson A, Egund N, Rydling O, Stockerup R, Ryd L. The natural history of recurrent dislocation of the patella: long-term results of conservative and operative treatment. *J Bone Joint Surg Br*. 1992;74(1):140-142.
3. Banke IJ, Kohn LM, Meidinger G, et al. Combined trochleoplasty and MPFL reconstruction for treatment of chronic patellofemoral instability: a prospective minimum 2-year follow-up study. *Knee Surg Sports Traumatol Arthrosc*. 2014;22(11):2591-2598.
4. Bereiter H, Gautier E. Die Trochleaplastik als chirurgische Therapie der rezidivierenden Patellaluxation bei Trochleadysplasie des Femurs. *Arthroskopie*. 1994;7:281-286.
5. Biedert RM, Netzer P, Gal I, Sigg A, Tscholl PM. The lateral condyle index: a new index for assessing the length of the lateral articular trochlea as predisposing factor for patellar instability. *Int Orthop*. 2011;35(9):1327-1331.
6. Bollier M, Fulkerson JP. The role of trochlear dysplasia in patellofemoral instability. *J Am Acad Orthop Surg*. 2011;19(1):8-16.
7. Camathias C, Pagenstert G, Stutz U, Barg A, Müller-Gerbl M, Nowakowski AM. The effect of knee flexion and rotation on the tibial tuberosity-trochlear groove distance [published online January 21, 2015]. *Knee Surg Sports Traumatol Arthrosc*. doi:10.1007/s00167-015-3508-9.
8. Caton J. Method of measuring the height of the patella [in French]. *Acta Orthop Belg*. 1989;55(3):385-386.
9. Dejour D, Saggin P. The sulcus deepening trochleoplasty: the Lyon's procedure. *Int Orthop*. 2010;34(2):311-316.
10. Dejour H, Walch G, Neyret P, Adeleine P. Dysplasia of the femoral trochlea [in French]. *Rev Chir Orthop Reparatrice Appar Mot*. 1990; 76(1):45-54.
11. Dejour H, Walch G, Nove-Josserand L, Guier C. Factors of patellar instability: an anatomic radiographic study. *Knee Surg Sports Traumatol Arthrosc*. 1994;2(1):19-26.
12. Desio SM, Burks RT, Bachus KN. Soft tissue restraints to lateral patellar translation in the human knee. *Am J Sports Med*. 1998; 26(1):59-65.
13. Dietrich TJ, Betz M, Pfirrmann CWA, Koch PP, Fucentese SF. End-stage extension of the knee and its influence on tibial tuberosity-trochlear groove distance (TTTG) in asymptomatic volunteers. *Knee Surg Sports Traumatol Arthrosc*. 2014;22(1):214-218.
14. Donell ST, Joseph G, Hing CB, Marshall TJ. Modified Dejour trochleoplasty for severe dysplasia: operative technique and early clinical results. *Knee*. 2006;13(4):266-273.
15. Duncan ST, Noehren BS, Lattermann C. The role of trochleoplasty in patellofemoral instability. *Sports Med Arthrosc*. 2012;20(3):171-180.
16. Dunn DM. Anteversion of the neck of the femur; a method of measurement. *J Bone Joint Surg Br*. 1952;34(2):181-186.
17. Dvorak J, George J, Junge A, Hodler J. Age determination by magnetic resonance imaging of the wrist in adolescent male football players. *Br J Sports Med*. 2007;41(1):45-52.
18. Fucentese SF, Zingg PO, Schmitt J, Pfirrmann CWA, Meyer DC, Koch PP. Classification of trochlear dysplasia as predictor of clinical outcome after trochleoplasty. *Knee Surg Sports Traumatol Arthrosc*. 2011;19(10):1655-1661.
19. Goutallier D, Raou D, Van Driessche S. Retro-trochlear wedge reduction trochleoplasty for the treatment of painful patella syndrome with protruding trochleae: technical note and early results [in French]. *Rev Chir Orthop Reparatrice Appar Mot*. 2002;88(7):678-685.
20. Hefti F, Müller W, Jakob RP, Stäubli HU. Evaluation of knee ligament injuries with the IKDC form. *Knee Surg Sports Traumatol Arthrosc*. 1993;1(3-4):226-234.
21. Heywood A. Recurrent dislocation of the patella—a study of its pathology and treatment in 106 knees. *J Bone Joint Surg Br*. 1961; 43(3):508-517.
22. Hiemstra LA, Kerslake S, Lafave MR, Heard SM, Buchko GML, Mohtadi NGH. Initial validity and reliability of the Banff Patella Instability Instrument. *Am J Sports Med*. 2013;41(7):1629-1635.
23. Hirschmann A, Buck FM, Herschel R, Pfirrmann CWA, Fucentese SF. Upright weight-bearing CT of the knee during flexion: changes of the patellofemoral and tibiofemoral articulations between 0° and 120°

[published online November 4, 2015]. *Knee Surg Sports Traumatol Arthrosc*. doi:10.1007/s00167-015-3853-8.
24. Koëter S, Pakvis D, van Loon CJM, van Kampen A. Trochlear osteotomy for patellar instability: satisfactory minimum 2-year results in patients with dysplasia of the trochlea. *Knee Surg Sports Traumatol Arthrosc*. 2007;15(3):228-232.
25. Kujala UM, Jaakkola LH, Koskinen SK, Taimela S, Hurme M, Nelimarkka O. Scoring of patellofemoral disorders. *Arthroscopy*. 1993; 9(2):159-163.
26. Lewallen LW, McIntosh AL, Dahm DL. Predictors of recurrent instability after acute patellofemoral dislocation in pediatric and adolescent patients. *Am J Sports Med*. 2013;41(3):575-581.
27. Maenpaa H, Lehto MUK. Patellar dislocation: the long-term results of nonoperative management in 100 patients. *Am J Sports Med*. 1997;25(2):213-217.
28. McNamara I, Bua N, Smith TO, Ali K, Donell ST. Deepening trochleoplasty with a thick osteochondral flap for patellar instability: clinical and functional outcomes at a mean 6-year follow-up [published online September 3, 2015]. *Am J Sports Med*. doi:10.1177/0363546515597679.
29. Nelitz M, Dreyhaupt J, Lippacher S. Combined trochleoplasty and medial patellofemoral ligament reconstruction for recurrent patellar dislocations in severe trochlear dysplasia: a minimum 2-year follow-up study. *Am J Sports Med*. 2013;41(5):1005-1012.
30. Nomura E, Horiuchi Y, Kihara M. Medial patellofemoral ligament restraint in lateral patellar translation and reconstruction. *Knee*. 2000;7(2):121-127.
31. Ntagiopoulos PG, Byn P, Dejour D. Midterm results of comprehensive surgical reconstruction including sulcus-deepening trochleoplasty in recurrent patellar dislocations with high-grade trochlear dysplasia. *Am J Sports Med*. 2013;41(5):998-1004.
32. Pfirrmann CW, Zanetti M, Romero J, Hodler J. Femoral trochlear dysplasia: MR findings. *Radiology*. 2000;216(3):858-864.
33. Post WR. Clinical evaluation of patients with patellofemoral disorders. *Arthroscopy*. 1999;15(8):841-851.
34. Rouanet T, Gougeon F, Fayard J-M, Rémy F, Migaud H, Pasquier G. Sulcus deepening trochleoplasty for patellofemoral instability: a series of 34 cases after 15 years postoperative follow-up. *Orthop Traumatol Surg Res*. 2015;101(4):443-447.
35. Schoettle PB, Zanetti M, Seifert B, Pfirrmann CWA, Fucentese SF, Romero J. The tibial tuberosity-trochlear groove distance; a comparative study between CT and MRI scanning. *Knee*. 2006;13(1):26-31.
36. Schöttle PB, Fucentese SF, Pfirrmann C, Bereiter H, Romero J. Trochleaplasty for patellar instability due to trochlear dysplasia: a minimum 2-year clinical and radiological follow-up of 19 knees. *Acta Orthop*. 2005;76(5):693-698.
37. Senavongse W, Amis AA. The effects of articular, retinacular, or muscular deficiencies on patellofemoral joint stability: a biomechanical study in vitro. *J Bone Joint Surg Br*. 2005;87(4):577-582.
38. Smith TO, Davies L, O'Driscoll M-L, Donell ST. An evaluation of the clinical tests and outcome measures used to assess patellar instability. *Knee*. 2008;15(4):255-262.
39. Sossai R, Vavken P, Brunner R, Camathias C, Graham HK, Rutz E. Patellar tendon shortening for flexed knee gait in spastic diplegia. *Gait Posture*. 2015;41(2):658-665.
40. Tegner Y, Lysholm J. Rating systems in the evaluation of knee ligament injuries. *Clin Orthop Relat Res*. 1985;198:43-49.
41. Tscholl PM, Antoniadis A, Dietrich TJ, Koch PP, Fucentese SF. The tibial-tubercle trochlear groove distance in patients with trochlear dysplasia: the influence of the proximally flat trochlea [published online October 19, 2014]. *Knee Surg Sports Traumatol Arthrosc*. doi:10.1007/s00167-014-3386-6.
42. Utting MR, Mulford JS, Eldridge JDJ. A prospective evaluation of trochleoplasty for the treatment of patellofemoral dislocation and instability. *J Bone Joint Surg Br*. 2008;90(2):180-185.
43. Verdonk R, Jansegers E, Stuyts B. Trochleoplasty in dysplastic knee trochlea. *Knee Surg Sports Traumatol Arthrosc*. 2005;13(7):529-533.
44. von Knoch F, Böhm T, Bürgi ML, Knoch von M, Bereiter H. Trochleaplasty for recurrent patellar dislocation in association with trochlear dysplasia: a 4- to 14-year follow-up study. *J Bone Joint Surg Br*. 2006;88(10):1331-1335.
45. Wagner D, Pfalzer F, Hingelbaum S, Huth J, Mauch F, Bauer G. The influence of risk factors on clinical outcomes following anatomical medial patellofemoral ligament (MPFL) reconstruction using the gracilis tendon. *Knee Surg Sports Traumatol Arthrosc*. 2013;21(2):318-324.
46. Zaki SH, Rae PJ. Femoral trochleoplasty for recurrent patellar instability: a modified surgical technique and its medium-term results. *Curr Orthop Practice*. 2010;21(2):153-157.